



Contents lists available at ScienceDirect

International Journal of Surgery Case Reports

journal homepage: www.casereports.com

Her-2 positive mucinous carcinoma breast cancer, case report

Irean Garcia Hernandez^a, Mauricio Canavati Marcos^b, Margarita Garza Montemayor^c, Dulce Lopez Sotomayor^a, Diana Pineda Ochoa^c, Gabriela Sofia Gomez Macias^{a,d,*}^a Tecnológico de Monterrey, San Jose Hospital, Pathology Service, Mexico^b Tecnológico de Monterrey, Breast Cancer Center, Mexico^c Tecnológico de Monterrey, Imaging Center Diagnostic of Breast, Mexico^d Hospital Universitario de la UANL, Faculty of Medicine, Mexico

ARTICLE INFO

Article history:

Received 18 August 2017

Received in revised form 8 December 2017

Accepted 14 December 2017

Available online 26 December 2017

Keywords:

Mucinous breast carcinoma

Her2 positive

Resistance trastuzumab

ABSTRACT

INTRODUCTION: Mucinous carcinoma is a variant of invasive breast carcinomas that accounts for 2% of them and has a better prognosis in contrast to the non-specific invasive carcinoma. They regularly are positive for estrogen and progesterone receptors and, generally, they do not overexpress HER2. When HER2 is positive, the first line treatment is trastuzumab; although the resistance is 52–89% for the non-specific carcinoma, it has been described just once in mucinous carcinoma.

CASE SUMMARY: A 48-year-old female presented with a lump in her right breast and after a biopsy, it was diagnosed as mucinous carcinoma in the core biopsy and surgical resection, with positive hormone receptors and HER2 positive (3+) in 100% of the tumor cells. She was treated with neoadjuvant chemotherapy based on trastuzumab and pertuzumab with no pathological response.

DISCUSSION: There are few pure mucinous carcinomas positive for HER2. Mucinous carcinomas are positive for HER2 account for less than 5% of invasive ductal carcinoma. Furthermore, our case was resistance to chemotherapy. Most mucinous carcinomas test negative for HER2, so they usually would not be treated with trastuzumab, in this case because the expression of HER2 in the biopsies we initiated it.

CONCLUSION: It's important to know that cases of mucinous carcinoma positive for HER2 exist and to be aware of the clinical problems that they may present: resistance to trastuzumab. Also, we need to understand the responsible mechanisms of this resistance and use immunohistochemistry for MUC which may predict it.

© 2018 The Authors. Published by Elsevier Ltd on behalf of IJS Publishing Group Ltd. This is an open access article under the CC BY-NC-ND license (<http://creativecommons.org/licenses/by-nc-nd/4.0/>).

1. Introduction

Mucinous breast carcinoma is a special variant of invasive breast carcinomas that accounts 2% of them. This variant has a better prognosis in contrast to the non-specific invasive ductal carcinoma. They regularly are positive for estrogen receptors, progesterone receptors [1] and they generally do not overexpress the HER2 (93%). It is important for physicians to know about this entity because there are no existence of protocols of treatment in Her2 mucinous carcinoma, and there is only one article using trastuzumab being resistance in mucinous carcinoma HER2 positive. This case report has been described under the SCARE criteria [18].

* Corresponding author at: Hospital San José Tecnológico de Monterrey, Pathology Service. Av. Morones Prieto 3000 Poniente, Los Doctores, 64710 Monterrey, NL, Mexico.

E-mail address: dra.gabrielagomez@tecsalud.mx (G.S. Gomez Macias).

<https://doi.org/10.1016/j.ijscr.2017.12.025>

2210-2612/© 2018 The Authors. Published by Elsevier Ltd on behalf of IJS Publishing Group Ltd. This is an open access article under the CC BY-NC-ND license (<http://creativecommons.org/licenses/by-nc-nd/4.0/>).

2. Case report

A 48-year-old Mexican female with family history of cancer (uncle with prostatic cancer), presented with a lump in her right breast. A core biopsy was taken and was diagnosed as a low grade infiltrating ductal carcinoma with positive estrogen and progesterone receptors and positive HER 2 (3+). She took 10 chemotherapy cycles (pertuzumab and trastuzumab) and, after this, she was referred to our institution for surgical management.

In our institution, an MRI showed a homogenous hyper-intense irregular mass with indistinct margins; on early phase image of dynamic enhancement the tumor showed an irregular shape, irregular margins and heterogeneous enhancement (Fig. 1). Revision of core biopsy's slides was reported as a grade 1 carcinoma with mucinous features, 100% positivity for estrogen receptors with high intensity, 90% for progesterone receptors with high intensity and 100% positivity for HER 2 (3+) (Fig. 2).

This case was revised in the Tumor Board of our institution. Because of the history of the patient and in the presence of a

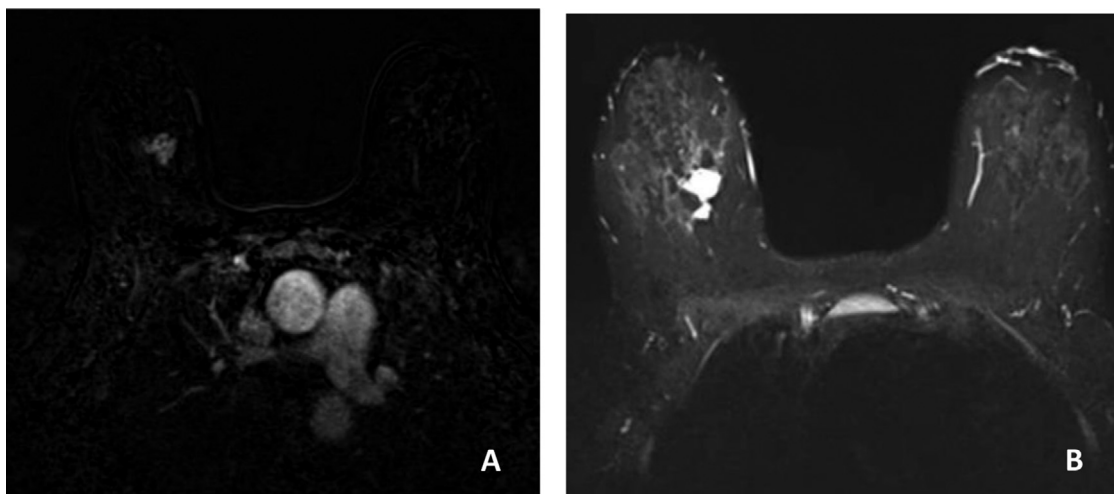


Fig. 1. A Axial T2- weighted TIRM MR sequence shows homogeneous hyperintense irregular mass. B, on early phase image of dynamic enhancement MRI, tumor shows irregular shape and irregular margin with heterogeneous enhancement is seen.

resectable mass, a simple mastectomy and sentinel lymph node biopsy was scheduled.

The surgical specimen showed a tumor of 2.2×1.9 cm which was 0.4 cm from the nearest surgical margin. It was heterogeneous, gelatinous, white-grayish, with lobulated margins and firm. Microscopically, the tumor showed multiple large lakes of extracellular mucin; inside them numerous tumor cells of medium to large size, with scant moderate amount of eosinophilic cytoplasm were found. Some presented in groups forming nests or tubes. These features were found in 100% of the lesion. It was diagnosed as a mucinous pure carcinoma which, with the Scarff Bloom Richardson Scale, was low grade (score 5). Also, we did not observe perineural or vascular invasion and the sentinel lymph node was negative for metastases. Immunohistochemistry was performed and the results were: 100% positivity for estrogen receptors with high intensity, 90% for progesterone receptors with high intensity and 100% positivity for HER2 (3+) (Fig. 3). Because of her previous medical treatment and according to the Miller and Payne system, the tumor was grade 1 (absence of pathological response). With all of this, it was classified as ypT2N0Mx (Fig. 3).

After this, we decided to continue adjuvant hormonal therapy and trastuzumab because of positivity for estrogen and progesterone receptors, and the expression of HER2.

3. Discussion

Carcinomas with mucin can be pure, mixed or can have only a mucinous component. A mucinous carcinoma is pure when the colloid component is present in at least 90% of the tumor and mixed if it's found in 75–90%. It is a slow-growing neoplasm; with an estimated growth rate of one third the one of the non-specific invasive ductal carcinoma of no special type (IDC) of the breast. [1]

Mucinous carcinoma is a variant of invasive breast carcinomas that represents only 2% of them [2–4]. Axillary lymph node metastases are rare (12–14%). They are usually low grade, positive for the estrogen and/or progesterone receptors and negative for HER2 receptor. Mucinous tumor cells are more responsive to hormonal treatment, and have a better prognosis than common types of invasive cancer.

Differentiation between pure mucinous carcinomas and mixed types by their mammographic features has been described in the literature [5]. However, the correlation between mammographic or sonographic findings and nuclear grade is scarce. Lam et al. [5] analyzed the mammographic and sonographic features of 33 mucinous

carcinomas; when the lesion was mammographically detectable, mucinous carcinomas commonly presented as a mass, either oval or lobular (24/26, 92.3%), with a circumscribed or a micro-lobulated margin (18/26, 69.2%). Circumscribed margins were found only in pure mucinous carcinoma (8/16, 50%), whereas indistinct margins were more commonly found in the mixed type. Few data are available on the sonographic appearance of mucinous carcinoma. Memis et al. [6] mentioned that echogenicity might be used to predict the histologic subtype because isoechoic masses were found in pure mucinous carcinoma, whereas hypoechoic masses were found in mixed mucinous carcinoma

The immunohistochemistry profile that they express, justifies their good behavior and prognosis. Ninety-four percent of them are positive for estrogen receptors, 81% for progesterone receptors [7,8,9] and 93% don't overexpress HER2.

Pure mucinous carcinoma is less likely to spread to the axillary lymph nodes than other types of IDC. Estimates on how often this happens vary, but on average it's thought to occur in 15%.

Twenty to 30% of IDC present positivity for HER2 but 52–89% [10] of them are resistant primary or secondarily to trastuzumab [11,12]. For carcinomas with mucin, this resistance has only been described once (Table 1). Baretta et al. [14], described two patients with HER2-positive mucinous component breast carcinoma which were treated with trastuzumab without response. In comparison to the present case, these had only a colloid component and were grade 3. Furthermore, in those cases the patients had positive lymph nodes and metastasis.

Diverse mechanisms of trastuzumab resistance have been described, but only two are related to the mucin production, specifically MUC4. These mechanisms are: 1) MUC4 acts as an anti-adhesion barrier or anti-recognition on the epithelial surface or tumor cells, 2) MUC4 binds to the tyrosine-kinase receptor ErbB2 and alters cellular signaling [15].

Rakha et al. found expression of MUC4, MUC5AC and MUC6 in 95, 37 and 20%, respectively, in 1447 breast carcinoma cases that were analyzed [13] and Carraway et al. described that 30% of breast carcinomas were positive to MUC [16]. Mucinous breast carcinoma expresses MUC 2 and MUC 6 but the frequency of MUC 4 expression is unknown.

The case presented, showed an immunohistochemistry profile positive for estrogen and progesterone receptors and HER2 overexpression. She was treated with surgical treatment after hormone therapy and we discussed the trastuzumab use because of the expression for HER2.

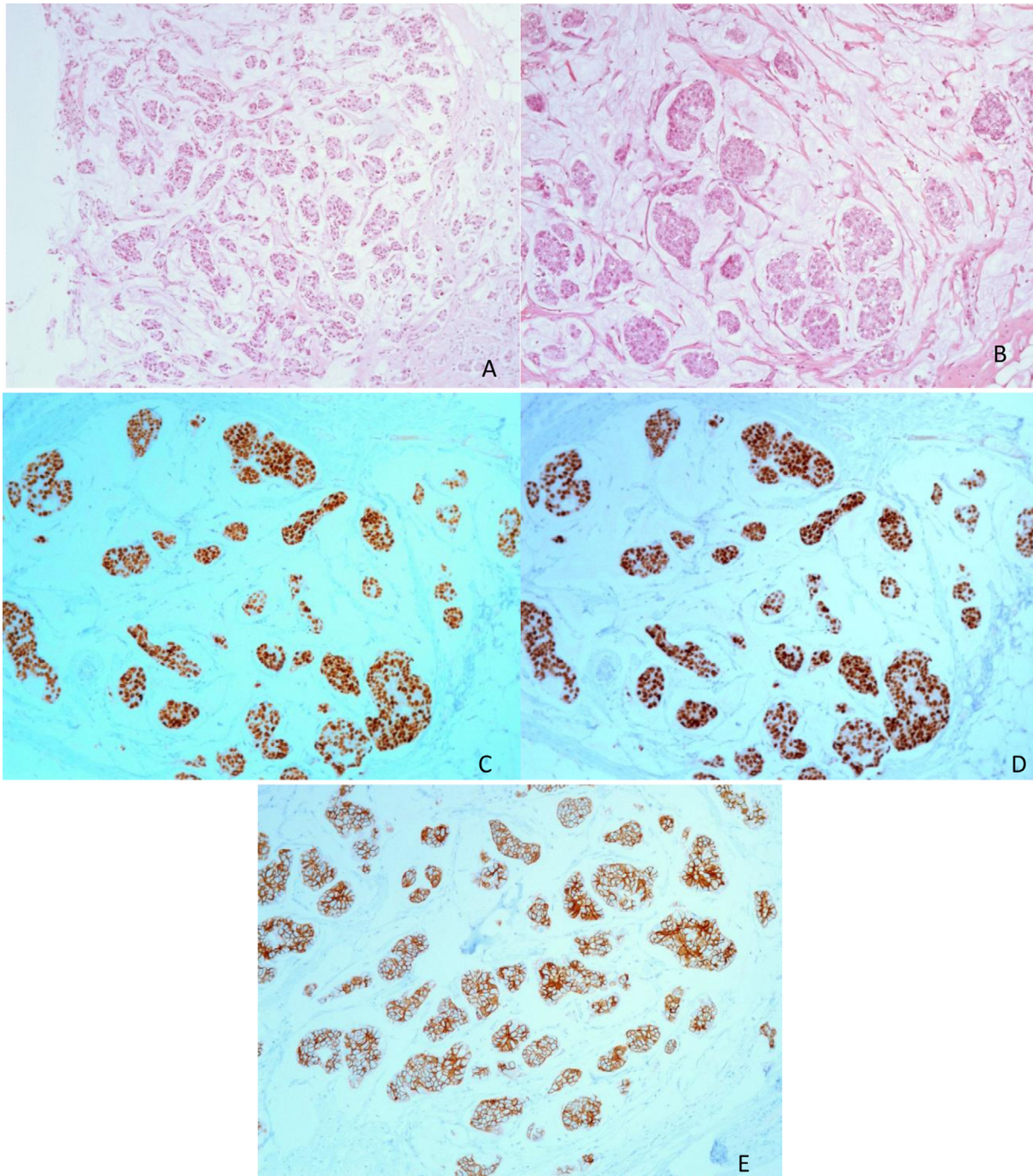


Fig. 2. Core biopsy (A) On panoramic view the tumor is composed of multiple groups of neoplastic cells immerse on extracellular mucin (hematoxylin-eosin). (B) Extracellular mucin lakes with are the prominent characteristic of the tumor. (C) ER was positive with 100% of neoplastic cells (D) PR was positive in the 100% of the cells. (E) Her2-neu (3+) 100% of the neoplastic cells.

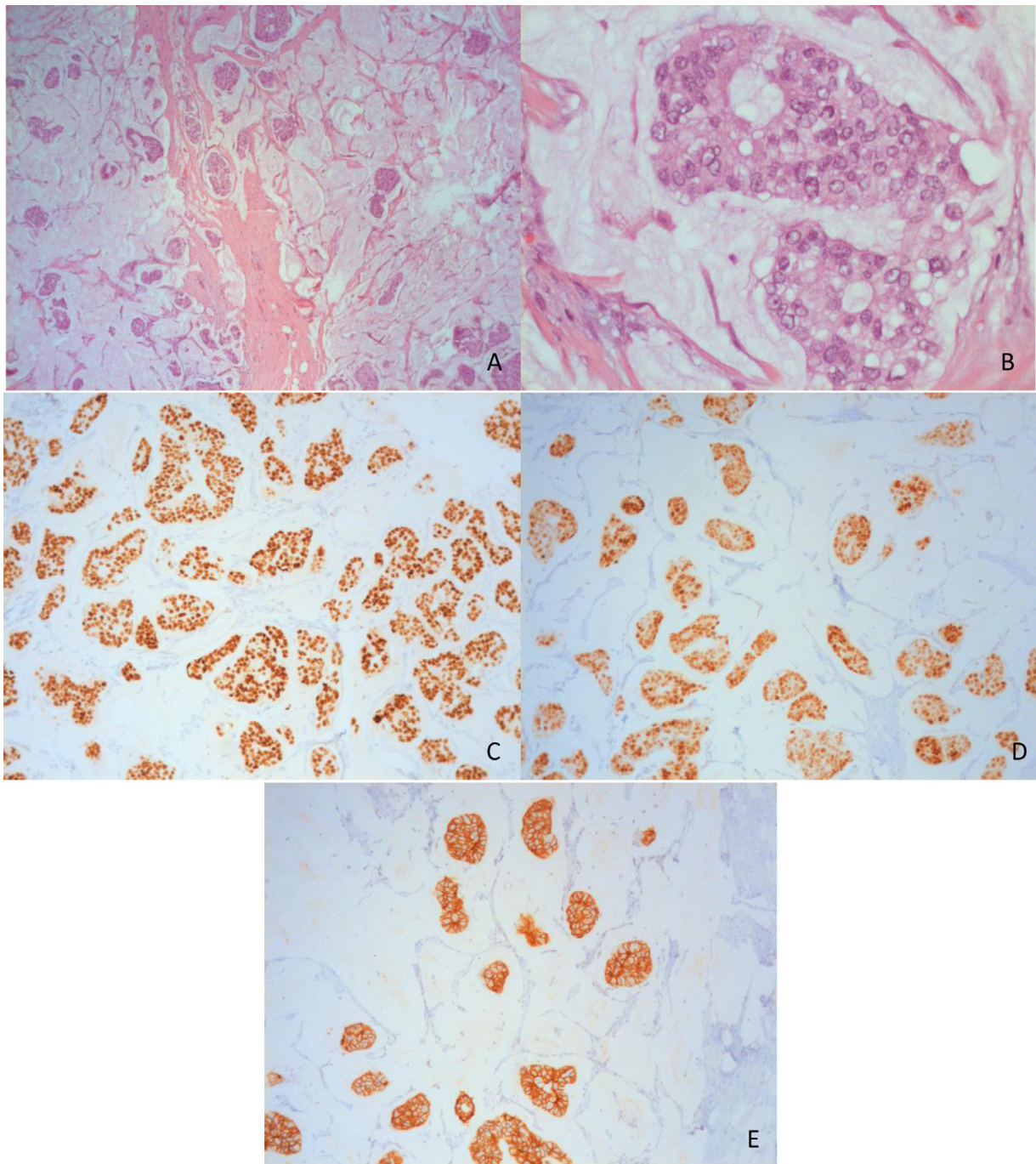


Fig. 3. Surgical resection (A) Panoramic view of the tumor is composed of multiple groups of neoplastic cells immerse on extracellular mucin (hematoxylin-eosin 4×). (B) Extracellular mucin lakes with are the prominent characteristic of the tumor (40×). (C) ER was positive with 100% of neoplastic cells (D) PR was positive in the 100% of the cells. (E) Her2-neu (3+) 100% of the neoplastic cells. Pathologic no response (pNR).

The primary protocol of treatment of mucinous breast carcinoma is surgery with post-operative endocrine therapy, which is indicated in hormone responsive tumors [17]. Most mucinous carcinomas test negative for receptors for the protein HER2/neu, so they usually would not be treated with trastuzumab.

Trastuzumab is approved for both the treatment of advanced breast cancer and as an adjuvant therapy for early-stage HER2-positive tumors. In this case, we decided to initiate trastuzumab treatment, so the importance of this article is because there's only one article using trastuzumab being resistant in mucinous carcinoma positive for HER2 [14] and this is the first one showing resistance in a pure one.

Conflicts of interest

We dont have any conflicts of interest.

Funding source

None.

Ethical approval

Ethical approval is exempt from our institution for case reports.

Table 1
Present and previously reported cases.

Case	Age	Pathological diagnosis	Mucinous area (%)	Grade	ER, PR, HER2 expression	Adjuvant therapy	Response
1	48	Pure mucinous carcinoma	100%	Grade 1	ER (+) PR (+) HER 2 (3+)	HT + pertuzumab Trastuzumab	Miller Payne 1 (pNR).
2 Zora Baretta et al.	57	IDC with mucinous component	<75%	Grade 3	ER (+) PR (–) HER2 (+)	CT (carboplatine, docetaxel) + RT + trastuzomab	Poor response.
3 Zora Baretta et al.	29	Breast with IDC and lung metastasis with mucinous component	<75%	Grade 3	ER (–) PR (–) HER 2 (+)	Carboplatine doc- etaxel + Trastuzumab.	Mixed response ^a .

ER, estrogen receptor, PR, progesterone receptor, HER2, human epidermal growth factor receptor 2, IDC, Infiltrating ductal carcinoma, HT, hormonal therapy, CT, chemotherapy, RT, radiotherapy, pNR, pathological no response.

^a Died two months after initiating treatment with lapatinib and capecitabine.

Consent

Written informed consent was obtained from the patient for publication of this case report and accompanying images. A copy of the written consent is available for review by the Editor-in-Chief of this journal on request

Author contribution

All author contributed equally in the conception and design, acquisition of data, analysis and interpretation of data, drafting the article and revising it critically for important intellectual content. It is adnexal at the end of this form.

Guarantor

We accept full responsibility for the work and conduct of the study.

References

[1] A. Dumitru, A. Procop, A. Iliesiu, et al., Mucinous breast cancer: a review study of 5 year experience from a hospital-based series of cases, *Medical* 201510 (1) (2016) 14–18.

[2] S.G. Diab, G.M. Clark, C.K. Osborne, et al., Tumor characteristics and clinical outcome of tubular and mucinous breast carcinomas, *J. Clin. Oncol.* 17 (1999) 1442–1448.

[3] C.I. Li, D.J. Uribe, J.R. Daling, Clinical characteristics of different histologic types of breast cancer, *Br. J. Cancer* 93 (2005) 1046–1052.

[4] S. Park, J. Koo, J.H. Kim, et al., Clinicopathological characteristics of mucinous carcinoma of the breast in Korea: comparison with invasive ductal carcinoma-not otherwise specified, *J. Korean Med. Sci.* 25 (2010) 361–368.

[5] W.W.M. Lam, W.C.W. Chu, G.M. Tse, T.K. Ma, Sonographic appearance of mucinous carcinoma of the breast, *Am. J. Roentgenol.* 182 (4) (2004) 1069–1074.

[6] A. Memis, N. Ozdemir, M. Parildar, E.E. Ustunn, Y. Erhan, Mucinous breast cancer: mammographic and US features with histologic correlation, *Eur. J. Radiol.* 35 (2000) 39–43.

[7] S. Di Saverio, J. Gutierrez, E. Avisar, A retrospective review with long term follow up of 11,400 cases of pure mucinous breast carcinoma, *Breast Cancer Res. Treat.* 111 (2008) 541–547.

[8] C.R. Barkley, J.A. Ligibel, J.S. Wong, et al., Mucinous breast carcinoma: a large contemporary series, *Am. J. Surg.* 196 (2008) 549–551, PubMed: 18809061.

[9] S.G. Diab, G.M. Clark, C.K. Osborne, et al., Tumor characteristics and clinical outcome of tubular and mucinous breast carcinomas, *J. Clin. Oncol.* 17 (1999) 1442–1448, PubMed: 10334529.

[10] D. Gajria, S. Chandralapaty, HER2-amplified breast cancer: mechanisms of trastuzumab resistance and novel targeted therapies, *Expert Rev. Anticancer Ther.* 11 (2) (2011) 263–275.

[11] N.L. Spector, K.L. Blackwell, Understanding the mechanisms behind trastuzumab therapy for human epidermal growth factor receptor 2- positive breast cancer, *J. Clin. Oncol.* 27 (2009) 5838–5847.

[12] S. Matsukita, M. Nomoto, S. Kitajima, et al., Expression of mucins (MUC1, MUC2, MUC5AC and MUC6) in mucinous carcinoma of the breast: comparison with invasive ductal carcinoma, *Histopathology* 42 (2003) 26–36.

[13] E.A. Rakha, R.W. Boyce, D. Abd El-Rehim, et al., Expression of mucins (MUC1, MUC2, MUC3, MUC4, MUC5AC and MUC6) and their prognostic significance in human breast cancer, *Mod. Pathol.* 18 (2005) 1295–1304.

[14] Zora Baretta, et al., Resistance to trastuzumab in HER2-positive mucinous invasive ductal breast carcinoma, *Clin. Breast Cancer* 13.2 (2013) 156–158.

[15] N.V. Adsay, K. Merati, H. Nassar, et al., Pathogenesis of colloid (pure mucinous) carcinoma of exocrine organs: coupling of gel-forming mucin (MUC2) production with altered cell polarity and abnormal cell-stroma interaction may be the key factor in the morphogenesis and indolent behavior of colloid carcinoma in the breast and pancreas, *Am. J. Surg. Pathol.* 27 (2003) 571–578.

[16] K.L. Carraway, S.A. Price-Schiavi, M. Komatsu, et al., Muc4/sialomucin complex in the mammary gland and breast cancer, *J. Mammary Gland Biol. Neoplasia* 6 (2001) 323–337.

[17] T. Nakagawa, K. Sato, M. Moriwaki, et al., Successful endocrine therapy for locally advanced mucinous carcinoma of the breast, *Breast J.* 18 (2012) 632–633.

[18] R.A. Agha, A.J. Fowler, A. Saetta, I. Barai, S. Rajmohan, D.P. Orgill, for the SCARE group, the SCARE statement: consensus-based surgical case report guidelines, *Int. J. Surg.* (2016).

Open Access

This article is published Open Access at [sciencedirect.com](https://www.sciencedirect.com). It is distributed under the [IJSCR Supplemental terms and conditions](#), which permits unrestricted non commercial use, distribution, and reproduction in any medium, provided the original authors and source are credited.